

CASE STUDY



Reconstruction of a Displaced Distal Radius with Volar Lunate Facet Fragment

The Surgeon

Durettie Fufa, MD - Hand and Upper Extremity and Trauma Surgeon

Dr. Duretti Fufa is a board certified orthopedic surgeon specializing in hand surgery with additional expertise in reconstruction and microsurgery. She earned her undergraduate and medical degrees from Harvard University before completing her orthopaedic surgery residency at Hospital for Special Surgery. Dr. Fufa completed fellowship training in hand and upper extremity surgery at Washington University in St. Louis. Her subspecialty training continued with a plastic surgery fellowship in trauma and microsurgery at Chang Gung Memorial Hospital in Taipei, Taiwan.

The Case



Patient Profile

A 25-year-old male was involved in a skateboard accident, sustaining immediate pain and swelling to the right wrist. He was evaluated at the emergency room where x-rays were performed, demonstrating a distal radius fracture. Closed reduction was performed. The patient presented to our hospital 3 days post-injury for evaluation of his right wrist. Computed tomography (CT) was performed at that time for surgical planning.



Pre-Treatment Imaging and Diagnosis

Initial x-rays show displaced distal radius fracture without ulnar fracture (Figure 1A). Subsequent CT scan of the distal radius demonstrated 23-C3 complete intra-articular fracture of the distal radius with comminution visualized on axial, coronal, and sagittal imaging (Figures 1B, 1C, and 1D, respectively). Notably, the fracture line was very distal at the ulnar margin, commonly referred to as the volar lunate facet. The patient was indicated for operative intervention with open reduction and internal fixation.



Pre-Treatment Imaging and Diagnosis

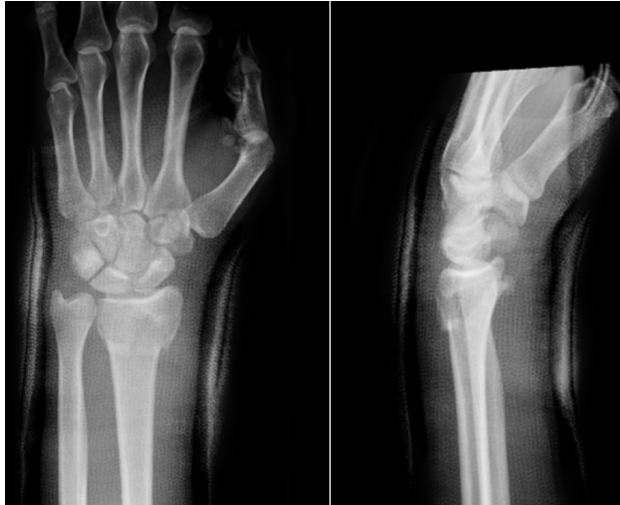

Figure 1A: Pre-Op Distal Radius Fracture

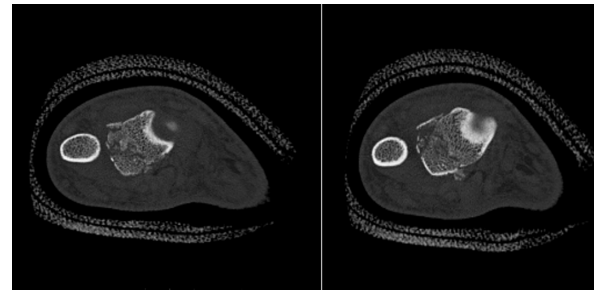


Figure 1B: Axial CT Scan

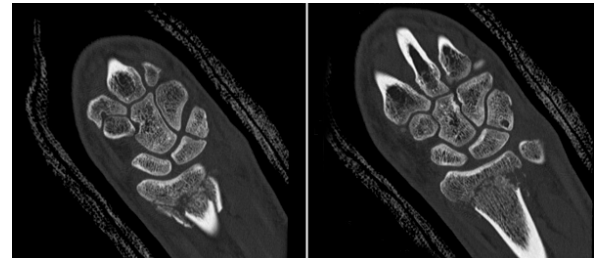


Figure 1C: Coronal CT Scan

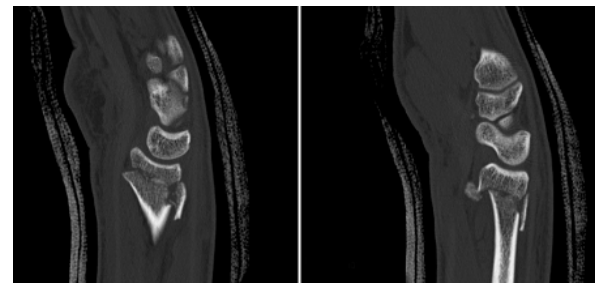
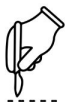

Figure 1D: Sagittal CT Scan



Surgical Treatment

A standard volar approach to the wrist starting just proximal to the wrist crease and extending along the flexor carpi radialis (FCR) tendon was used. The FCR sheath was incised and the FCR tendon retracted ulnarly to protect the radial artery and palmar cutaneous branch. The flexor pollicis longus was then retracted ulnarly, revealing the pronator quadratus. The pronator quadratus was elevated in an L-fashion off of the distal radius, starting with a limb from radial to ulnar, then a limb from distal to proximal, along the volar surface of the radius. The fracture site was identified and mobilized.

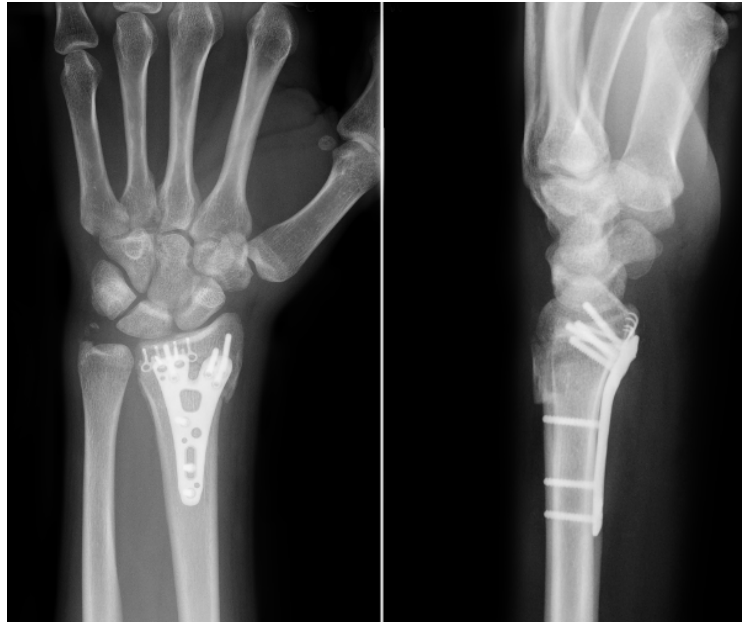Reduction was performed by placing a volar to dorsal Kirschner wire on the radial articular fragment. Once anatomic reduction was visualized, due to the need for distal plate position, the Medartis FPL sparing volar distal radius plate was placed provisionally using a Kirschner wire and a shaft screw in the oblong hole. The 4-hole hook plate was placed beneath the volar plate along the ulnar rim and a bone tamp was utilized to impact the hooks to the volar capsular tissue. Plate positions were checked on anteroposterior and lateral fluoroscopy. After the desired plate position was obtained, a second screw was placed in the most proximal diaphyseal hole of the volar plate. Three diaphyseal cortical screws were used to obtain proximal fixation. For distal fixation, a single locking screw was placed in the ulnar-most aspect of the distal row. Fluoroscopy was used to verify plate position and reduction before the remaining distal holes were also filled with locking screws.

Four 1.5 Speedtip screws were inserted to the hook plate to stabilize it beneath the volar plate, ensuring their trajectory was aiming proximal, away from the joint line. Final fluoroscopic images demonstrated fracture reduction with no intraarticular screw penetration and Soong grade 1 volar plate prominence. Evaluation of wrist range of motion produced no evidence of instability or prominent hardware at the distal radial ulnar joint (Figures 2 and 3).



Post-Operative Treatment

The patient's right arm was immobilized in a well-padded volar wrist splint and sling post-operatively. At two weeks, the incision was healed, the stitches were removed, and the patient was referred to hand therapy for volar resting splint and gradual strengthening. At three months, the patient returned to work and nearly all pre-injury activities, excluding contact sports, with no pain or numbness.



Figures 2 and 3: 2-weeks Post-Op



Conclusion

Open reduction and internal fixation of the distal radius was achieved with particular attention paid to stabilization of the volar lunate facet with the 4-hole hook plate. This plate allowed for lower profile plate prominence distally without sacrificing stabilization. The patient had a good functional result with no restrictions in range of motion or weightbearing activities. Additionally, there was no fracture subsidence, tendon irritation, or rupture requiring additional surgery in his postoperative course. The Medartis volar hook plate can be considered in distal fractures where volar and distal plate prominence may cause flexor tendon irritation.

This case study was produced with assistance from Research Assistant, Jarod Chow, B.S.

Disclaimer: This information is intended to demonstrate the Medartis portfolio of medical devices. A surgeon must always rely on her or his own professional clinical judgment when deciding whether to use a particular product when treating a particular patient. Medartis is not giving any medical advice. The devices may not be available in all countries due to registration and / or medical practices. For further questions, please contact your Medartis representative (www.medartis.com). This information contains CE-marked products. For US only: Federal law restricts this device to sale by or on the order of a physician